

ROLE OF SEPTOPLASTY AND FUNCTIONAL ENDOSCOPIC SINUS SURGERY IN THE TREATMENT OF RHINOGENIC HEADACHE

Authors: Jagram Verma (1) Ritu Verma Ahirwar (2)

Authors Affiliations: (1) Associate Professor, (2) Resident, Department of Otorhinolaryngology, MGMMC, Indore (M. P)

ABSTRACT

INTRODUCTION: Rhinogenic headaches are basically described as headache or facial pain caused by rhinological source. The presence of nasal symptoms & it's temporal relationship with headache is the key factor that can guide the diagnosis and patient management.

AIMS: This study aims to evaluate the efficacy of Septoplasty with Functional endoscopic sinus surgery (F.E.S.S) in the management of rhinogenic headache.

MATERIALS & METHODS: It was a Prospective study conducted in M.G.M Medical College & associated M.Y group of hospitals from March 2019 to March 2020. 64 patients of age group 18 years to 60 years having chronic rhinosinusitis with headache included in the study. After detailed history and thorough examination, nasal endoscopy and CT Paranasal sinus was done. Patients not responding to conservative management were selected for undergoing functional endoscopic sinus surgery.

RESULTS: A total of 64 patients were included in the study, 34 male & 30 female with the mean age group of 31.4 & 30.1 years respectively. Out of 64 patients, 67% were completely free from headache, 15% were significantly improved, 7% had mild relief & 11% did not show any benefit in headache from surgery. Postoperatively, there was statistically significant difference was found patient's symptomatology (i.e. p value = 0.0165).

CONCLUSION: To make the diagnosis both anatomical & infective factors needed to be considered. correction of obvious anatomic abnormalities in carefully selected patients can significantly improve several important clinical outcomes from abolishing headache completely to

decreasing its intensity and frequency of episodes.

KEY-WORDS: Rhinogenic headaches, Septoplasty, Chronic rhinosinusitis, F.E.S.S, Nasal endoscopy

INTRODUCTION

Rhinogenic headaches are basically described as headache or facial pain caused by rhinological source. The conditions causing rhinogenic headaches are also described by International Headache Society (IHS) and the American Academy of Otolaryngology-Head and Neck Surgery (AAOHNHNS).

Evidently, when ventilation of the sinus outflow tract is inadequate or completely obstructed, there occurs marked increase in pressure within the sinuses causing mucosal inflammatory changes and pain. The characteristics of facial pain, its location, severity, frequency and duration remain important. The presence of nasal symptoms & its temporal relationship with headache is the key factor that can guide the diagnosis and patient management.

In past many decades, numerous studies have documented about the overall subjective improvement of headaches and facial pain following surgeries that are either directed at various contact points between 2 opposing mucosal surfaces within the nasal cavities, most commonly observed between an osseous spur along a deviated nasal septum and the adjacent middle or inferior nasal turbinate, or between a large concha bullosa and the lateral nasal wall.⁽¹⁾ Patients with refractory headaches are often very likely to have signs of underlying sinonasal inflammatory change or they can demonstrate contact points on CT or endoscopy, and thus benefit from the nasal surgery directed to

the underlying inciting pathology.(2)

The major objectives of these procedures include improving nasal flow, improving ventilation & drainage in addition to removal of polyps, in patients of refractory Chronic Rhinosinusitis or recurrent Acute Rhinosinusitis.(3)

The present study aims to assess the clinical and relevant pathological profile of the patients with headache in Chronic Rhinosinusitis subjects and to evaluate the efficacy of Septoplasty alone and Septoplasty with Functional endoscopic sinus surgery in the management of these patients.

MATERIALS AND METHODS

It was a Prospective study conducted in M.G.M Medical College & associated M.Y group of hospitals from March 2019 to March 2020. 64 patients of age group 18 years to 60 years were included in the study. *Inclusion criteria:* Patients having chronic rhinosinusitis with headache fulfilling the diagnostic criteria of International Classification of Headache Disorders (ICHD 3) (5) not responding to conservative management were included in the study. *Exclusion criteria:* Patients of age below 18 years and patients having headache due to causes other than sinusitis, pregnant women & patients with bleeding diathesis were excluded from the study.

Subjects were further divided in Group A (30) & Group B (34). Group A patients underwent septoplasty only. In Group B, both septoplasty & Functional endoscopic sinus surgery was performed.

Detailed history of all the presenting symptoms like nasal discharge (whether watery, mucoid or purulent), nasal obstruction (onset, duration, frequency) recurrent sneezing, postnasal discharge or any associated aural or allergic pathology was taken. Thorough ENT examination was conducted with more emphasis on anterior and posterior rhinoscopy. On *Anteriorrhinoscopy*, septal deviation, caudal dislocation, nasal cavity patency, condition of nasal mucosa, status of middle and inferior turbinate (hypertrophy, atrophy, curvature), nasal discharge (watery, mucoid, purulence) and presence or absence of any nasal mass was noted. On *Posterior rhinoscopy*, character of post nasal discharge, posterior ends of turbinate, presence of any polypoidal mass and nasopharyngeal end of

eustachian tube was assessed.

DNE (Diagnostic nasal endoscopy) was done in all subjects using 0° and 30° endoscopes. To achieve local anesthesia and decongestion, prior nasal packing was done with 4% lignocaine and xylometazoline solution. The patients underwent computed tomography scan of paranasal sinuses and coronal and axial sections (when required) were obtained. CT(Computed tomography), due to its exquisite ability to display and differentiate hypertrophic mucosa, bone, and air, is the current imaging standard for the evaluation of sinonasal anatomy.(4)

The diagnosis was made by using International Classification of Headache Disorders (ICHD 3)(5) as follows Clinical, nasal endoscopic and/or imaging evidence of current or past infection or other inflammatory process within the paranasal sinuses. Evidence of causation demonstrated by at least two of the following:

- headache has developed in temporal relation to the onset of chronic rhinosinusitis
- headache waxes and wanes in parallel with the degree of sinus congestion and other symptoms of the chronic rhinosinusitis
- headache is exacerbated by pressure applied over the paranasal sinuses
- in the case of a unilateral rhinosinusitis, headache is localized and ipsilateral to it
- Not better accounted for by another ICHD-3 diagnosis.

Patients diagnosed with headache associated with chronic rhinosinusitis refractory to medical treatment and with supportive diagnostic nasal endoscopy and radiological findings were selected for undergoing either Septoplasty alone or along with FESS.

Septoplasty was always performed first followed by middle turbinectomy in order to gain access to the medial wall of ethmoid cells. The patients with paradoxically curved middle turbinate were treated by endoscopic medialization/lateralization of the middle turbinate, whereas the patients with concha bullosa were treated by lateral resection of the pneumatized concha. Patients with enlarged

ethmoid bulla underwent bullectomy.

The mucosal contacts were removed by endoscopic approach (lateral concha bullosa resection, endoscopic Septoplasty) or conventional endonasal procedures (septoplasty according to Cottle). The intensity of pain was evaluated by Visual Analogue Score (VAS) before medical treatment, and at two months after therapy by medications, as well as before surgical treatment, one month, six months after the surgery. The facial pain was scored as follows: 0, absence of pain; 1–3, mild pain; 4–6, moderately severe pain; 7–9, severe pain; 10, the worse pain imaginable.

We used the Paired *t* test (two-tailed *t* test) for the evaluation of variable means in each group and we assumed a significance level of 0.05.

RESULTS

A total of 64 patients were included in the study, 34 male & 30 female with the mean age group of 31.4 & 30.1 years respectively (Table 1). The majority (29) of patients were belonging to 21 to 30 age group. Followed (15) by 31 to 40 age group. Age groups 18–20 & 41–50 had comparable (9,8 respectively) incidences, while least commonly involved was 51–60 group showing only 3 cases. In the study we found male preponderance, as 34 male and 30 females were included, male to female ratio being 1.14:1. The study included 64 patients having both chronic nasal obstruction and headache along with other variable symptoms. In other symptoms, most frequent was nasal discharge found in 42 patients followed by recurrent sneezing (24) and post nasal drip (23) (Table 2). The pain due to sino-nasal pathology was found to be radiating primarily to four sites, frontal being the most common (69%). 14 % patients had retroorbital & 14% patients had diffused type of headache. Only 3% patients complained of medial canthal pain (Figure 1).

Anterior rhinoscopy was done in all the subjects in which nasal mucosa was found normal in majority (51%) of patients but hyperemic in 17% and pale in 31% signifying chronic nature of disease. Nasal septum deviation was the most common (87%) finding, that also lead to compensatory inferior turbinate hypertrophy in majority (70%) of patients. Followed by middle turbinate hypertrophy in 43(67%) patients and spur in 35 (55%), nasal polyp in 12(19%) patients respectively.

Diagnostic nasal endoscopy showed DNS (Deviated nasal septum) in 59 patients, 37 U/L (unilateral) & 22 B/L (bilateral), ITH (inferior turbinate hypertrophy) in 53, 29 U/L & 24 B/L, MTH (middle turbinate hypertrophy) in 47 & spur (Figure 1a) in 40 patients 32 U/L & 14 B/L. Pus in the middle meatus was found in 21 patients 14 U/L & 7 B/L. CT PNS (CT Paranasal sinuses) Coronal section Mucosal contact point in 41 patients U/L & 3 patients B/L. Concha bullosa (Figure 1c) was found in 28, U/L & 11, B/L. Paradoxical MT was seen in 23 U/L & 3 B/L. Enlarged bulla in 16 cases, only one being B/L. While uncinate was found enlarged in 9 patients only (Table 3). CT PNS Coronal view showed mucosal abnormality, most commonly involved sinus was maxillary sinus in 38 patients followed by anterior ethmoid in 28, posterior ethmoid in 18. Least commonly involved was frontal & sphenoid sinuses (Table 4).

Septoplasty was done in all the cases, followed by spurectomy (Figure 1b) in 40 and middle meatus antrostomy in 34, anterior ethmoidectomy in 28, concha exteriorization (Figure 1d) in 18, middle turbinate lateralization in 15, inferior turbinate cautery in 14 cases (Figure 2).

Overall, 54 patients were relieved in nasal obstruction leaving 10 with residual symptom, out of 42 patients, 13 continued to have nasal discharge, 10 headache, 5 post nasal drip & 3 aural fullness (Table 5). Recurrent sneezing was least relieved by the operative intervention, showing allergic nature of its etiology. Postoperatively, there was statistically significant difference between pre & postoperative frequency of symptoms (i.e p value = 0.0165).

Out of 64 patients, 67% were completely free from headache, 15% were significantly improved, 7% had mild relief & 11% did not show any benefit in headache from surgery. In Group A ($n=30$) in which only Septoplasty was performed showed reduction in headache in 24 (79%) patients. In Group B ($N=34$) in which both septoplasty & fess was performed, 30 (89%) patients showed benefit in headache postoperatively (Figure 3). Statistically, there was no significant difference in the outcome of headache postoperatively in 2 groups (p value > 0.05).

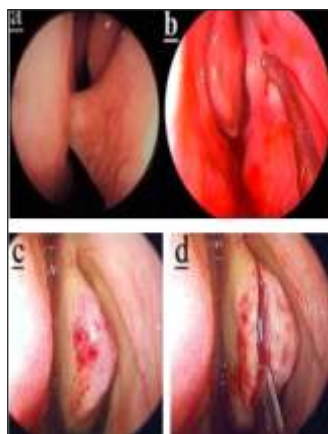


Figure 1 (a)showing endoscopicpictureof septalspur touching inferior turbinate (b)showing intraoperative endoscopicimageafter spurectomy(c) & (d)showing endoscopic imageof concha bullosa (left sided) and conchoplasty respectively.

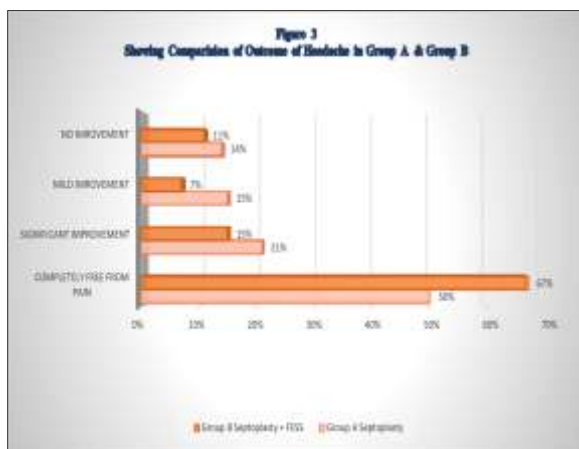
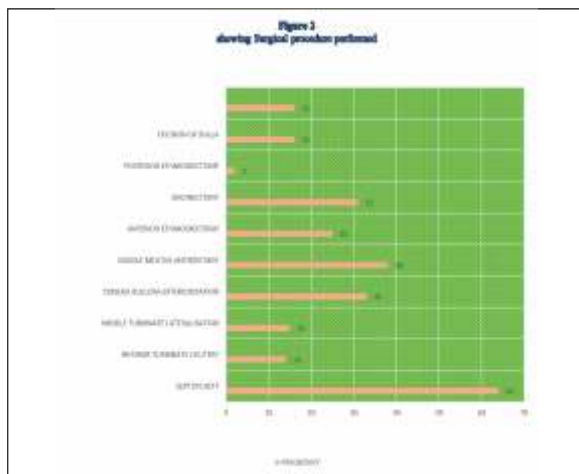


Table 1: Patient characteristics

	Frequency	Percentage (%)	Mean age (in years)
male	34	53	31.40
female	30	47	30.16

Table 2: Main symptoms during preoperative evaluation

Symptom	Frequency	Percentage (%)
Nasal obstruction	64	100
Nasal discharge	42	65
Headache	64	100
Post nasal drip	23	36
Recurrent sneezing	24	37
Aural fullness	14	22

Table 3: Osteomeatal Complex finding on CT Paranasal Sinus (Coronal section).

Finding	Total	Percentage	Unilateral	Percentage	Bilateral
		Percentagefrequency	(%)	(%)	
Concha bullosa	39	61	28	71	11
Enlarged bullaethmoidalis	16	25	15	94	1
Enlargeduncinateprocess	9	14	2	100	7
Medially bentuncinate process	11	17	10	91	1
Paradoxicalmiddleturbinate	26	40	23	88	3
Mucosal contactpoint	44	69	41	93	3

Table 4: Mucosal abnormalities detected on CT PNS (coronal view)

Site of involvement	Frequency	Percentage (%)	Bilateral	Percentage (%)	Unilateral	Percentage (%)
Anteriorethmoid	28	43	15	53	13	47
Maxillary	38	59	13	34	25	66
Frontal	3	4	-	-	3	100
Posteriorethmoid	18	28	7	39	11	61
Sphenoid	1	1	-	-	1	100
Diffuse mucosalhypertrophy	4	6	1	25	3	75

Table 5: Overall Subjective Improvement in Symptoms

Nasal obstruction	64	10	84
Nasal discharge	42	13	69
Headache	64	10	84
Post nasal drip	23	5	78
Recurrent sneezing	24	14	42
Aural fullness	14	3	78

DISCUSSION

In the cases of facial pain and headache attributed to contact points, secondary to rhinosinusitis, patients invariably have coexisting symptoms of nasal obstruction, rhinorrhea and alteration of smell.(6) Many anatomic variations of the structures in the middle meatus can narrow the stenotic clefts even more and thus predispose to more or less intense contact of opposing mucosal surfaces. This may impede or block ventilation and drainage of the ethmoid and surrounding larger sinuses and thus affect those as well. In our study, we found the most intensive pain sensation in patients with septal spur. Duration and frequency of headaches are highest in patients with mucosal contacts associated with septal spur. It seems that pressure between mucosal surfaces in small area of septal spur peak results in more intensive sense of pain than in the cases of septal deviation and concha bullosa. After identification of these underlying causes, functional endoscopic sinus surgery with usually minimal operations often can provide dramatic relief of symptoms that may have been present for months or even years.(7)

Age-Sex Distribution

In our study, out of 64 patients, 34(53%) was male & 30(47%) were female with M:F ratio being 1.13:1 and majority (46%) belonged to 21-30 year age group. In a similar study, *Sangeeta Aggarwal et al*(8) had a total of 50 patients, in which 35 were male & 15 were female with mean age of 28.96 years.

Pre-operative Symptoms

Verma et. Al. (9) in their study of 100 patients found that in patients of nasal obstruction, nasal discharge was the predominant symptom (80%) followed by headache(60%) sneezing (30%), post nasal drip (20%). In our study we observed nasal discharge in

65% patients, post nasal drip in 36%, recurrent sneezing in 37% & aural fullness was least common (22%).

Localization of headache

In present study we noted medial canthal and retro orbital pain in 17% patients followed by diffused (17%). In another study done by *Rai UL et al*. (2018)(10) noted highest in frontal region headache in 82% followed by periorbital (34%) & diffused (4%). *Laxamanan et. al*(11) reported maximum (48%) in frontal region & periorbital in 14% patients.

Anterior rhinoscopy & Nasal endoscopy findings

In the study, the findings on anterior rhinoscopy & diagnostic nasal endoscopy were found to be similar for most of the parameters. Although some findings like posteriorly lying nasal septal deviation and septal spur were better visualized in DNE. In present study the predominant sign was deviated nasal septum (92%) followed by inferior turbinate hypertrophy (83%). In another similar study by *Maurya et. al*, IT hypertrophy was seen in 83% while DNS in 69% & mucosal congestion in 21%, we noted it in 17% cases. Concha bullosa was the most prevalent (61%) variation of middle turbinate in our study, followed by paradoxical middle turbinate (40%), enlarged bulla (25%), medially bent uncinate (17%), enlarged uncinate in 14% cases.

Mucosal changes in CT Paranasal Sinus

Maxillary sinus was the most commonly involved sinus (59%), followed by anterior ethmoid (43%), posterior ethmoid (28%), frontal & sphenoid were the least commonly found to be involved 4% & 1% respectively. *Verma et. al* also reported involvement of maxillary sinus in maximum (50%) patients, anterior ethmoids in 40%, posterior ethmoids in 30% comparable to our observations.

Postoperative subjective improvement in other symptoms

The relief in nasal obstruction was by 91%, in nasal discharge 76%, post nasal drip in 86% & aural fullness by 95% respectively. We found statistically significant difference ($p=0.0165$) in the preoperative & postoperative symptom frequency. In a similar study by *Verma et. al*, comparable results were found, relieve in nasal obstruction by 80% & 87%, in rhinorrhea 67% & 75% in septoplasty & septoplasty + FESS respectively. *Chandrashekarappa et. al*, also noted postop reduction in nasal obstruction by 84% & post nasal drip by 74%.

Postoperative improvement in headache

There are several studies that have analyzed the success of the surgery of rhinogenic headache. The criteria for inclusion and the results were different from study to study. The biggest series, which was presented by *Huang et al* (12), included 66 patients divided into three groups: with deviation of the nasal septum, with concha bullosa, and with orbitoethmoidal (Haller's) cell. After the surgical treatment, the authors found a reduction of intensity and frequency of headache in 81.8% of the patients. *Parsons and Batra* (13) demonstrated an improvement rate of 91% in a retrospective study including 34 subjects with contact between the septum and nasal turbinates. *Sadeghi et al* published similar results (improvement in 93.3% of patients) with similar groups for a total of 30 patients (14). Our results, with an improvement rate of 80% (Group A) and 88.2% (Group B), is generally in accordance with previously published results.

LIMITATIONS

The study has its limitation as it has a follow up period of only 6 months. Also, a larger sample size would increase the variability of symptoms and understanding of problem in terms of an effective surgical outcome with surgical intervention and adequate disease improvement.

CONCLUSIONS

Headache related to the sinonasal inflammation and infections are very common. Surgical correction of obvious anatomic abnormalities in carefully selected patients can significantly improve several important clinical outcomes including abolishing headache completely to decreasing its intensity and frequency in patients with chronic rhinosinusitis and headaches. The results of surgical treatment are better in cases of headache associated with the presence of septal spur and concha bullosa than in those associated with nasal septal deviation.

CONFLICT OF INTEREST

The author(s) declare(s) that there is no conflict of interest.

REFERENCES

1. Tosun F, Gerek M, Özkaptan Y. Nasal Surgery for Contact Point Headaches. *Headache J Head Face Pain*. 2000;40(3):237–40.
2. Patel ZM, Kennedy DW, Setzen M, Poetker DM, DelGaudio JM. "Sinus headache": rhinogenic headache or migraine? An evidence-based guide to diagnosis and treatment. *Int Forum Allergy Rhinol*. 2013;3(3):221–30.
3. Chen Y-Y, Huang T-C. Outcome of Septoplasty with Inferior Turbinectomy as an Inpatient or Out-patient Procedure. *Sci Rep*. 2019 May 20;9(1):7573.
4. Verma J, Rathaur S, Mishra S, Mishra AK. The role of diagnostic imaging in evaluation of nasal and paranasal sinus pathologies. *Int J Otorhinolaryngol Head Neck Surg*. 2016 Jul 5;2:140.
5. Gobel H. ICHD-3 The International Classification of Headache Disorders 3rd edition [Internet]. ICHD-3 The International Classification of Headache Disorders 3rd edition. [cited 2020 Aug 14]. Available from: <https://ichd-3.org/>
6. Jayawardena ADL, Chandra R. Headaches and Facial Pain in Rhinology. *Am J Rhinol Allergy*. 2018 Jan 1;32(1):12–5.
7. H S, G W. Headaches and sinus disease: the endoscopic approach. *Ann Otol Rhinol Laryngol Suppl*. 1988 Sep 1;134:3–23.
8. Aggarwal S, Sharma DK, Kaur R, Ramdev B, Rishi P, Sharma SR. Comparative Evaluation of Septoplasty versus Septoplasty with Functional Endoscopic Sinus Surgery (FESS) in 50 Cases of Chronic Maxillary Sinusitis. 2020;(2):8.
9. Verma et al. - 2019 - Retrospective and prospective study of septoplasty.pdf [Internet]. [cited 2020 Sep 9]. Available from: <https://d1wqtxts1xzle7.cloudfront.net/63498570/IJASHNB-5-1-31-3320200601-152011bk0c0s.pdf>
10. Rai. Contact point headache: Diagnosis and management in a tertiary care center in Northeast India [Internet]. [cited 2020 Sep 11]. Available from: <http://www.jmedsoc.org/article.asp?issn=09724958;year=2018;volume=32;issue=1;page=51;epage=56;aulast=Rai>
11. Lakshmanan S, Singh U, Zaffrullah NS, Manimaran V. Clinical Outcome Following Endoscopic Septoturbinal Surgeries for Rhinogenic Contact Point Headache: A Retrospective Analysis. *Indian J Otolaryngol*

Head Neck Surg [Internet]. 2020 Mar 5 [cited 2020 Sep 9]; Available from: <http://link.springer.com/10.1007/s12070-020-01825-w>

12. Behin F, Behin B, Behin D, Baredes S. Surgical management of contact point headaches. *Headache*. 2005 Mar;45(3):204–10.
13. Parsons DS, Batra PS. Functional endoscopic sinus surgical outcomes for contact point headaches. *The Laryngoscope*. 1998 May;108(5):696–702.
14. Behin F, Behin B, Bigal ME, Lipton RB-Surgical Treatment of Patients with Refractory Migraine Headaches and Intranasal Contact Points, 2005 [Internet]. [cited 2020 Jul 28]. Available from <https://journals.sagepub.com/doi/abs/10.1111/1/j.1468-2982.2004.00877.x>
15. Behin F, Behin B, Behin D, Baredes S. Surgical Management of Contact Point Headaches. *Headache J Head Face Pain*. 2005;45(3):204–10.

***Corresponding Author:**

Dr. Ritu Verma Ahirwar
MIG 2nd 29 Pt. Deen Dayal Nagar
Makronia, Sagar, M. P
Email ID: ritikagmc@gmail.com
Contact no.: 8770151259

How to cite the article

Verma J, Ahirwar RV- Role of septoplasty and functional endoscopic Sinus surgery in the treatment of rhinogenic headache- UPJOHNS- Vol.-9, Issue-I, June 2021
DOI: <http://doi.org/10.36611/upjohns/volume9/Issue1/2>